

---

## CASE REPORT

# LIPOMA AT THE FLOOR OF MOUTH

Naheed Akhtar Jadoon and Kamran Iqbal

Gomal Medical College, D.I.Khan, Pakistan

## ABSTRACT

Lipomas mostly develop in the subcutaneous tissues but deeper tissues may be involved as well; the oral cavity is not commonly affected. The overall incidence in the oral cavity is thought to be between 1% and 4.4% of all benign intraoral lesions. The present report shows a 60 years old male who presented with large intraoral mass on the floor of the tongue. Excision biopsy was performed and the histological report proved to be a lipoma.

## INTRODUCTION

The peak incidence of lipomas is in the fifth or sixth decades of life while it is uncommon in children. Mostly lipomas develop in the subcutaneous tissues but deeper tissues may be involved as well; the oral cavity is not commonly affected.<sup>1</sup> The overall incidence in the oral cavity is between 1% and 4.4% of all benign oral lesions.<sup>2,3</sup> Oral lipomas can occur in various anatomic sites including the major salivary glands, buccal mucosa, lip, tongue, palate, vestibule, and floor of mouth.<sup>4,5</sup> Although benign in nature, their continuous growth may cause interference with speech and mastication due to tumors' dimension. Some studies showed a female preponderance while others did not found gender preference.<sup>4,6</sup>

## CASE REPORT

A 60 years old patient came to OPD with a cystic swelling in the floor of mouth approximately 5 cm in size. (Fig.1) A longitudinal incision was given over the tumor. Blunt dissection was used through out and the lesion literally popped out from the surrounding.

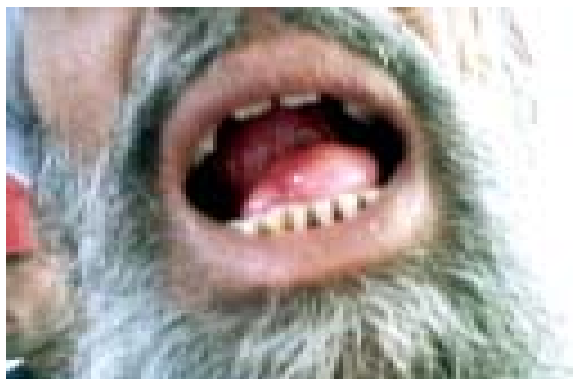


Fig. 1: Picture showing swelling on the floor of the mouth.

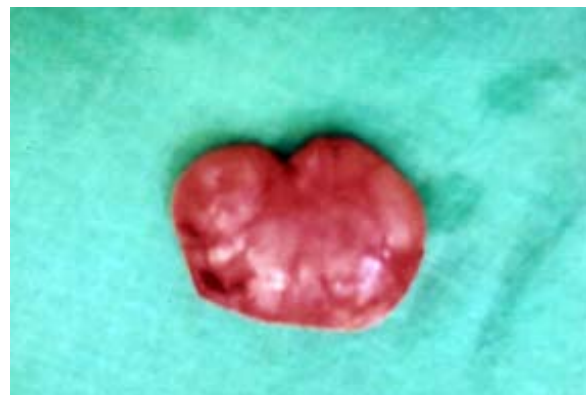

Fig. 2: Swelling in the floor of mouth after excision.

## DISCUSSION

Mostly lipomas develop in the subcutaneous tissues rarely they develop in the deep tissues. The most commonly involved sites are trunk and the lower limbs and seldom the oral and maxillofacial region.<sup>1,6</sup> The occurrence is higher in females than males with the ratio 2:1 but oral are more common in men than women or have no gender predilection.<sup>7</sup> Lipomas may develop in patients over 40 years old, the buccal mucosa and vestibule are the most commonly involved intraoral sites. Superficial lipomas in oral and maxillofacial region sometimes can be clinically diagnosed. Palpation reveals a soft, painless, and mobile mass, which gradually enlarges over the course of several months or years. Usually, deep lipomas are not palpable. It is difficult to distinguish between the mass and the adjacent tissues, especially when the mass is adherent to muscles and salivary glands. Hence, the imaging examination may be necessary. There are many imaging techniques that could be used to identify soft tissue masses, such as computerized tomography (CT), magnetic resonance imaging (MRI) and ultrasonography. Ultrasonography is suitable for

evaluation of superficial structures, like oral and maxillofacial region when the mass is difficult to identify on ultrasonogram, CT or MRI is necessary. Lipoma has a characteristic radiographic appearance. On CT scan it shows a high density from 83 to 143 Haunsfield units with well or poorly defined margins depending on the capsule. Despite the close histological similarity to normal adipose tissue, lipomas usually have chromosomal aberrations such as translocations involving 12q13-15, locus interstitial deletions of 13q, and rearrangements involving 8q11-13 locus.<sup>8</sup> The clinical differential diagnosis includes ranula, dermoid cyst, thyroglossal duct cyst, ectopic thyroid tissue, pleomorphic adenoma and mucoepidermoid carcinoma, angioliipoma, fibrolipoma and malignant lymphoma.<sup>9-11</sup> A histopathologic differential diagnosis appropriate to the oral cavity would include fibrosarcoma if spindle cells are not localized and numerous.<sup>12</sup> Other lesions should be also considered: they include schwanoma, myxoid-neurofibroma, leiomyoma, nodular fasciitis, myxolipoma, fibrolipoma, malignant fibrous histiocytoma, myxoidliposarcoma, and myxoid solitary fibrous tumor.

The prognosis of this tumor is always good. In adults, the recurrence is rare after complete resection; nonetheless, Cao reported recurrence in patients under 18 years age and development of liposarcoma after several recurrences. Long-term follow-up is necessary in patients under 18 years old.<sup>13</sup> Complete resection should be emphasized during the first surgical operation, which is the key factor in order to avoid recurrence.<sup>14</sup> Well encapsulated lipomas, as the present case, easily shell out with no possibility of recurrence or damage to the surrounding structures.

## REFERENCES

1. Dattilo DJ, Ige JT, Nwana EJ. Intraoral lipoma of the tongue and submandibular space: Report of a Case. *J Oral Maxillofac Surg* 1996; 54: 915-7.
2. Fregnani ER, Pires FR, Falzoni R, Lopes MA, Vargas PA. Lipomas of the oral cavity: clinical findings, histological classification and proliferative activity of 46 cases. *Int J Oral Maxillofac Surg* 2003; 32: 49-53.
3. Lombardi T, Odell EW. Spindle cell lipoma of the oral cavity: report of a case. *J Oral Pathol Med* 1994; 23: 237-9.
4. Jablowk VR and Bavafa S. Lipomas of the Tongue—report of two cases. *J Surg Oncol* 1982; 21: 114-6.
5. Fasig JH, Robinson RA, McCulloch TM, Fletcher MS, Miller CK. Spindle cell lipoma of the parotid: fine-needle aspiration and histologic findings. *Arch Pathol Lab Med* 2001; 125: 820-1.
6. Epivatianos A, Markopoulos AK, Papanayotou P. Benign tumors of adipose tissue of the oral cavity: a clinicopathologic study of 13 cases. *J Oral Maxillofac Surg* 2000; 58: 1113-7.
7. MacGregor AJ and Dyson DP. Oral lipoma. A review of the literature and report of twelve new cases. *Oral Surg Oral Med Oral Pathol* 1966; 21: 770-7.
8. Enzinger FW and Weiss SW. *Soft tissue tumors*. 4<sup>th</sup> ed. St. Louis: Mosby 2001.
9. Del Castillo Pardo de Vera JL, CebrianCarretero JL, Gomez Garcia E. Chronic lingual ulceration caused by lipoma of the oral cavity. Case report. *Med Oral* 2004; 9: 166-7.
10. Capodiferro S, Scully C, Maiorano E, Lo Muzio L, Favia G. Liposarcoma circumscriptum (lipoma-like) of the tongue: report of a case. *Oral Dis* 2004; 10: 398-400.
11. Piattelli A, Rubini C, Fioroni M, Iezzi G. Spindle-cell lipoma of the cheek: a case report. *Oral Oncol* 2000; 36: 495-6.
12. Tosios K, Papanicolaou SI, Kapranos N, Papadogeorgakis N. Spindle cell lipoma of the oral cavity. *Int J Oral Maxillofac Surg* 1995; 24: 363-4.
13. Zhong LP, Zhao SF, Chen GF, Ping FY. Ultrasonographic appearance of lipoma in the oral and maxillofacial region. *Oral Surg Oral Med Oral Pathol Oral Radiol Endod* 2004; 98: 738-40.
14. Furlong MA, Fanburg-Smith JC, Childers EL. Lipoma of the oral and maxillofacial region: site and subclassification of 125 cases. *Oral Surg Oral Med Oral Pathol Oral Radiol Endod* 2004; 98: 441-50.

## Corresponding author:

Naheed Akhtar Jadoon  
Gomal Medical College  
D.I.Khan, Pakistan