

# PERSISTENT HOARSENESS AND THE ASSESSMENT OF LARYNGEAL MUCOSAL LESIONS BY MICROLARYNGOSCOPY

Khurshid Anwar, Johar Iqbal, Mohammad Said, Mohammad Raza, Mohammad Riaz, Muneeb

Department of ENT and Head & Neck Surgery, KGN Teaching Hospital, Bannu Medical College, Bannu, and PGMI /Hayatabad Medical Complex, Peshawar, Pakistan

## ABSTRACT

**Background:** Hoarseness has a diverse etiology. Most of the causes are benign but the possibility of laryngeal cancer warrants early investigation and treatment. This study was conducted to determine the etiology of hoarseness in our setup and highlight the importance of microlaryngoscopy in the management of hoarseness. **Methods:** This prospective study was conducted at the department of ENT, PGMI/HMC, Peshawar from January 1, 2010 to June 30, 2011. A total of 76 cases were included in the study. The indication for microlaryngoscopy was persistent hoarseness of voice. All the patients underwent microlaryngoscopy and the apparently benign looking lesions were excised. In others, examination was limited to determination of extent and taking biopsy from the lesions. Diagnosis was made on the basis of laryngoscopic/biopsy findings. The results were analyzed using SPSS 10.0 for windows. **Results:** A total of 76 patients were included in this study. The male to female ratio was 1.7:1. The type of laryngeal mucosal lesions as determined on microlaryngoscopy was; vocal cord nodules 33%, vocal cord polyps 20%, recurrent respiratory papillomatosis 10.52%, cyst 7.89%, chronic granulomatous inflammation 5.26%, Reinke's edema 3.94%, chronic non specific granulomas 2.6% and subglottic hamangioma 1.31%. Two (2.36%) cases were having leukoplakia of the vocal cord and 13.15% cases were diagnosed as malignant. **Conclusion:** Chronic persistent hoarseness occurs due to a variety of causes, the majority of which are benign in nature. Microlaryngoscopy is a useful tool for the investigation of patients presenting with chronic persistent hoarseness.

**KEY WORDS:** Direct Laryngoscopy, Microlaryngoscopy, Hoarseness.

## INTRODUCTION

Hoarseness is a generic term used to describe a wide range of vocal abnormalities. The voice may sound breathy, raspy, strained, fatigued or show changes in volume or pitch. In a routine busy ENT OPD, hoarseness is a very common complaint. Nearly one-third of the population has impaired voice production at some point in their lives. Hoarseness is more prevalent in certain groups, such as teachers and older adults, but all age groups and both genders can be affected.<sup>1</sup> In the UK, It is estimated that otolaryngology/voice clinics receive over 50 000 patients with dysphonia each year.<sup>2</sup> Though common, hoarseness is merely a symptom and not a diagnosis and therefore warrants a careful determination of the underlying cause in every case.<sup>3</sup>

The etiology of hoarseness is very diverse and the etiological data varies greatly. Half of all patients presenting with a voice complaint have a benign lesion of the vocal fold.<sup>4</sup> The major three being nodules, polyps and cysts. The possibility

of laryngeal cancer warrants early investigation and treatment. Therefore, it is common practice to refer a patient to an otolaryngologist if the hoarseness persists for more than three weeks.<sup>5</sup>

An evaluation of the hoarse patient always starts with a careful history and physical examination. Visual inspection of the larynx by indirect laryngoscopy yields insufficient information. Office based flexible direct laryngoscopy is performed on awake patient and therefore not suitable for examining a child, anxious or uncooperative patient. This makes proper assessment of the pathology difficult.<sup>6</sup> Direct laryngoscopy under general anaesthesia is indicated for the assessment of hoarseness if symptoms do not resolve within three months, or earlier if the clinician suspects a serious underlying disorder.<sup>7</sup>

Microlaryngoscopy is the visualization of larynx under general anaesthesia with the help of direct laryngoscope and operating microscope using 400 mm lens. It allows the surgeon to use both hands and at the same time provides both magni-

fication and superior illumination of the field. It provides a surgical approach for obtaining biopsies and the excision of benign lesions, such as papillomas, polyps, nodules, cysts, webs and the excision of early squamous cell carcinomas (e.g. carcinoma in situ, T1).<sup>8</sup> However, in microlaryngoscopy extreme technical precision is required in order to disturb the mucosa minimally.

This study was conducted to determine the etiology of hoarseness in our setup and highlight the importance of microlaryngoscopy in the management of hoarseness.

### MATERIAL AND METHODS

This observational study using the non-probability convenience sampling technique was conducted at the ENT Department, Post-graduate Medical Institute, Hayatabad Medical Complex, Peshawar, from January 1, 2010 to June 30, 2011.

The study included 76 cases presenting with hoarseness of voice. Sample size was calculated using 95% confidence level, 20% prevalence of the disease and 9% margin of error as per WHO software for sample size determination.

Patients of all ages and both sexes, presenting with hoarseness for more than three weeks were included. Diagnosed cases of hoarseness presenting for follow up, hoarseness associated with upper respiratory tract infection, and functional or psychogenic hoarseness were excluded from the study.

Informed consent was obtained from every patient after explaining the procedure. A detailed history was obtained. ENT and systemic examination were carried out in every case. Baseline investigations were ordered in all cases to assess the patients' general condition and fitness for the procedure. The following laboratory investigations were carried out, as and when necessary;

Complete blood picture, screening for hepatitis B and C, blood sugar & urea levels, serum creatinine & electrolytes estimation, LFTs, urine R/E, ECG, echoardiography, x-ray chest & other imaging studies such as CT & MR imaging.

Microlaryngoscopy was carried out in all the cases using Storz operating microscope with 400mm focal length. In adults broad lumen direct laryngoscope of the Klein Sasser type was used while in children Storz Pediatric or Benjamin laryngoscopes were used. Any mucosal abnormality was noted in larynx and pathology dealt with accordingly. The mobility of the vocal cord was assessed during recovery phase. Any lesion excised was sent for histopathological examination.

All the data was collected on a proforma designed for the purpose. The data was analyzed using SPSS version 10.0 for windows. Descriptive statistics like mean  $\pm$  standard deviation were calculated for quantitative variables like age and duration of symptoms. Frequency and percentages were calculated for categorical variables like Gender, Inflammation and mucosal lesions. All these results were represented as tables.

### RESULTS

A total of 76 patients were included in this study. The ages of the patients ranged from 5-70 years with the mean age of  $\pm$  38 years with a std. deviation of 14.6. This included 48 males and 28 females with a male to female ratio of 1.7:1. The age wise frequency of various laryngeal mucosal lesions is detailed in Table 1. The commonest cause of hoarseness was vocal cord nodules in 25 followed by vocal cord polyps in 15 patients. Ten patients were diagnosed as having malignant mucosal lesions. Eight patients were found to have recurrent respiratory papillomatosis whereas vocal cord cysts were observed in 6 cases. Chronic laryngitis and Reinke's edema as a cause of chronic persistent hoarseness were seen in four and three

**Table 1: Age wise distribution the laryngeal mucosal lesions.**

Age (years)	Frequency	Percent	Cumulative Percent
<15	5	6.6	6.6
16 - 35	43	56.6	63.2
36 - 55	22	28.9	92.1
>55	6	7.9	100

**Table 2: The gender distribution of laryngeal mucosal lesions.**

S. No.	Type of Mucosal lesion	Male	Female
1	Vocal Cord Nodules	12	13
2	Vocal Cord Polyps	8	7
3	Respiratory Papillomatosis	5	3
4	Vocal Cord Cysts	6	0
5	Chronic Inflammation	2	2
6	Reinke's Oedema	0	3
7	Granuloma	2	0
8	Haemangioma	1	0
9	Leukoplakia	2	0
10	Malignant	10	0

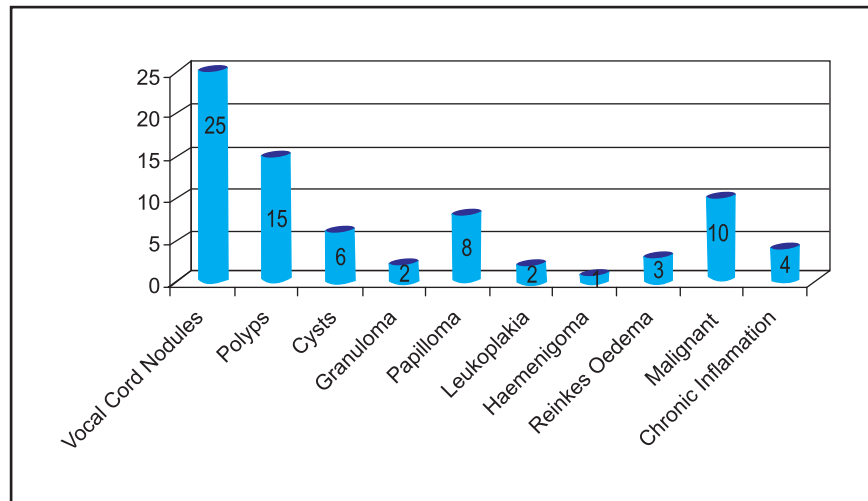


Fig. 1: The frequency of various laryngeal mucosal lesions.

patients respectively. Granuloma and leukoplakia were diagnosed in two cases each while only one patient was having haemangioma as shown in Figure 1.

Malignancy accounting for 10 cases was diagnosed only in males. The gender wise distribution of laryngeal mucosal lesion is shown in Table 2. Seventy two patients were having hoarseness for less than 3 years in contrast to 4 who had hoarseness for more than 3 years. The detail has been shown in Table 2.

## DISCUSSION

Indirect laryngoscopy is the traditional method of assessing the hoarse patient, however microlaryngoscopy is indispensable to make a more accurate assessment.<sup>9</sup> Benign lesions can usually be dealt with at the same sitting. The procedure is restricted to only taking biopsy from suspicious malignant lesions.

In our study, vocal cord nodules were the commonest benign lesions followed by vocal cord polyps. Nodules correlate strongly with voice abuse and appear as bilateral, smooth, rounded lesions on the cords. Small early nodules subside with speech therapy, microsurgical resection is only required if the symptoms are significant, conservative measures fail or if there is doubt of the diagnosis.<sup>10</sup> Microlaryngoscopy was both diagnostic and therapeutic for all these cases.

Polyps are related to smoking and are usually unilateral.<sup>11</sup> They are a cause for chronic persistent hoarseness. Most polyps need removal under a general anaesthetic.<sup>12</sup> Laryngeal cysts are usually obstructed mucous glands or epithelial inclusion. Small cysts may be difficult to detect on indirect laryngoscopy. They appear as a

smooth submucosal swelling on microlaryngoscopy and are frequently accompanied by a swelling on the opposite cord due to contact trauma. This may cause confusion with nodules and lead to inappropriate treatment. Microlaryngoscopy is therefore essential for making a correct diagnosis.<sup>13</sup> Reinke's oedema is the accumulation of fluid in the subepithelial connective tissue spaces. Early cases may resolve with speech therapy and smoking cessation; vocal cord stripping at microlaryngoscopy is usually required to treat the condition.

Recurrent respiratory papillomatosis is characterized by multiple warty lesions in the larynx affecting mostly children <5 years. It is caused by human papillomavirus types 6 and 11. The reported incidence of recurrent respiratory papillomatosis in the United States is at 4.3 per 100,000 children and 1.8 per 100,000 adults.<sup>14</sup> The recommended treatment is surgical excision /laser application at microlaryngoscopy. Eight patients with recurrent respiratory papillomatosis in our study were 2-5 years of age. All these cases were evaluated with microlaryngoscopy. Papillomas were removed with microforceps at microlaryngoscopy. Those with extensive papillomatosis were referred to specialized centers for LASER treatment after airway debulking.

In patients having suspicion of malignancy, microlaryngoscopy was restricted to examining the extent and taking biopsies from the lesions. Six patients in our series had posterior laryngeal ulceration. Two cases proved to be those of chronic non specific inflammation and 4 cases had chronic granulomatous inflammation. In one series by Kalindoros DC and colleagues, isolated laryngeal tuberculosis was present in 33% of patients.<sup>15</sup> Two patients with a history of smoking were having leu-

koplakia involving both vocal cords. Leukoplakia is a "white patch" that cannot be wiped off the vocal cords and may be precancerous. Its malignant transformation rate varies from 1% to 40%, with the highest rates being found in patients microscopically diagnosed as "keratosis with atypia".<sup>16</sup> Early and correct diagnosis is therefore essential to achieve a cure.

Ten patients presenting with hoarseness had malignant tumors of larynx thus emphasizing the need for proper laryngeal visualization in all such cases. Seven out of ten had T1 tumor and 3 patients had carcinoma in situ. Microsurgical resection of early vocal cord carcinoma has been found to be useful<sup>17</sup>. The vocal outcome following this procedure has improved by minimizing the deep resection margin and thereby maximizing the preservation of vocal folds. In terms of survival rates, T1 tumors involving anterior commissure demonstrate control rates of 93% as compared to 60% in T2.<sup>18</sup>

In Wisconsin, Dailey and colleagues while comparing the results of office based rigid telescopic stroboscopic laryngoscopy and microlaryngoscopy found that the former technique was liable to miss certain lesions and recommended microlaryngoscopy as the final diagnostic step in the evaluation of glottic pathology because it allowed meticulous inspection and palpation of the glottis during the procedure.<sup>6</sup>

## CONCLUSION

Chronic persistent hoarseness occurs due to a variety of causes, the majority of which are benign in nature. Microlaryngoscopy is a useful tool for the investigation of patients presenting with chronic persistent hoarseness. The technique is both diagnostic and therapeutic for the benign lesions and will help in early detection of those at risk of or having a laryngeal malignancy.

## REFERENCES

1. Roy N, Merrill RM, Thibeault S. Prevalence of voice disorders in teachers and the general population. *J Speech Lang Hear Res* 2004; 47: 281-93.
2. Syed I, Daniels E, Bleach NR. Hoarse voice in adults: an evidence-based approach to the 12 minute consultation. *Clin Otolaryngol* 2009; 34: 54-8
3. Waleem SU, Ali S, Ishaque M. Etiology of hoarseness- a study of 100 cases. *Pak J Otolaryngol* 2005; 21: 39-41.
4. Kleinsasser O. Microlaryngoscopy and endolaryngeal microsurgery: technique and typical findings. *Laryngoscope* 1979; 89: 247-52.
5. Goten AD. Evaluation of the patient with hoarseness. *Eur Radiol* 2004; 14: 1406-15.
6. Dailey SH, Spanou K, Zeitels SM. The evaluation of benign glottic lesions: rigid telescopic stroboscopy versus suspension microlaryngoscopy. *J Voice* 2007;21:112-8.
7. Schwartz SR, Cohen SM, Dailey SH, Rosenfeld RM, Deutsch ES, Gillespie MB, et al. Clinical practice guideline:Hoarseness (Dysphonia). *AAO-HNS Found*:2009;1-31.
8. Mcglashan J. Disorders of the voice. In: Michael Gleeson, Hibbert J, editors. *Scott-Brown, otorhinolaryngology, head and neck surgery*. Great Britain: Hodder Arnold press, 2008; 167: 219.
9. Clark AR, Murry T. Diagnostic laryngeal endoscopy. *Otolaryngol Clin Nor Am* 2000; 33: 751-7.
10. Gray SD, Hammond E, Hansen DF. Benign pathologic responses of the larynx, *Ann Otol Rhinol Laryngol* 1995; 104: 13-8.
11. Kleinsasser O. Microlaryngoscopy and histological appearances of polyps, nodules, cysts, Reinke's oedema, and granulomas of the vocal cords. In: Kirchner JA, ed. *Vocal fold histopathology: a symposium*. San Diego: College-Hill Press, 1986: 51-5.
12. Benninger MS. Microdissection or microspot CO2 laser for limited vocal fold benign lesions: A prospective randomized trial. *Laryngoscope* 2000; 110: 1-17.
13. Merati AL, Andrews RJ, Courey MS, Garrett CG, Ossoff RH. Phonosurgical management of intracordal cysts-operating Techniques. *J Otolaryngol* 1998; 9: 230-7
14. Derkay CS, Wiatrak B. Recurrent respiratory papillomatosis: a review. *Laryngoscope* 2008 ; 118: 1236-47
15. Kalindoros DC, Nikoloponloos TP, Ferekidis EA, Tsangaroulakis A, Yiotakis JE, Davilis D. Laryngeal TB at the end of 20<sup>th</sup> century. *J Laryngol Otol* 1997;111:619-21.
16. Bouquot EJ, Gnepp DR. Laryngeal precancer: A review of the literature, commentary and comparison with oral leukoplakia. *Head Neck* 1991; 13: 488-97.
17. Zeitels SM. Phono microsurgical treatment of early glottis cancer and carcinoma in situ. *Am J Surg* 1996; 172: 704-9.
18. Mark S, Persky, Victor O, Leary. Laryngeal radiotherapy for anterior commissure laryngeal carcinoma. *Ann Otol Rhinol Laryngol* 2000; 109: 155-9.

## Corresponding author:

Dr. Khurshid Anwar  
Senior Registrar, ENT Department  
KGNTH/Bannu Medical College  
Bannu, Pakistan  
E-mail: dr.khurshidanwar@yahoo.com