
IMAGES IN CLINICAL MEDICINE

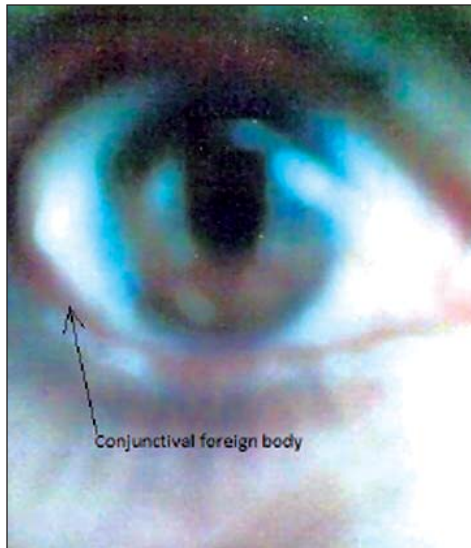


Fig. 1: Showing conjunctival foreign body.

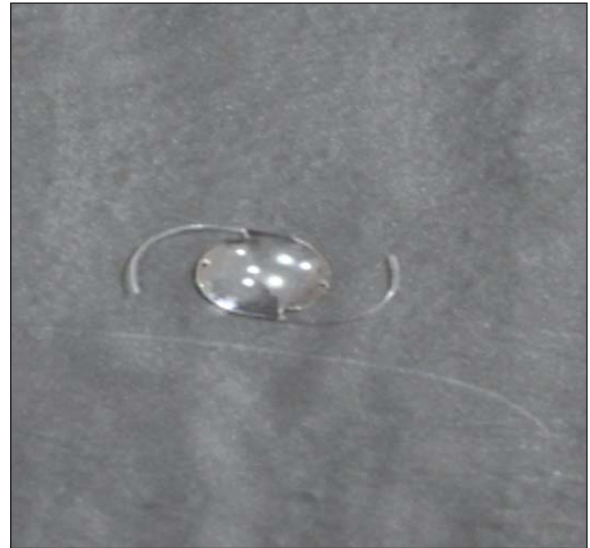

Fig. 2: Recovered intra ocular lens after washing.

FOREIGN BODY CONJUNCTIVA

This young mason of 30 years age from a nearby village never had any eye problem or surgery in the past. He presented with foreign body sensation and redness in his right eye for a couple of weeks. According to the patient, a foreign body lodged in his eye during routine masonry work.

On exploration, to our astonishment an intraocular lens covered with mucus was lying in the superior fornix of the conjunctival sac. From where it came, it is still a question.

Iftikhar Ahmad

Assistant Prof. Community Medicine
& Consultant Ophthalmologist
Gomal Medical College
D.I.Khan, Pakistan
E-mail: iftikharahmadgandapur@yahoo.com