

EDITORIAL

FOREIGN BODIES IN THE EAR, NOSE, AND THROAT: CLINICAL CHALLENGES AND MANAGEMENT

Nawazish Ali, Muneeba Attique

Departments of ENT, DHQ Teaching Hospital, Dera Ismail Khan, Pakistan

A foreign body is defined as any object or substance present in a part of the body where it does not normally belong. Foreign bodies involving the ear, nose, and throat (ENT) constitute one of the most frequent emergencies encountered in otorhinolaryngology outpatient clinics and emergency departments worldwide.¹ Despite advances in healthcare delivery and increased public awareness, these cases continue to pose a significant clinical challenge, accounting for nearly 11% of all ENT emergencies. Children, particularly those under three years of age, are the most affected population and experience the highest rates of morbidity and mortality. Foreign bodies may be lodged in natural orifices such as the external auditory canal, nasal cavity, pharynx, or aerodigestive tract, or may penetrate the soft tissues of the maxillofacial region.²

The types of foreign bodies vary according to age. In adults, common objects include dentures, metallic pins, screws, pellets, and meat or bone fragments. In contrast, children frequently present with plastic toys, seeds, stones, stationery items, coins, and fruit seeds. The tendency in children to insert objects into body orifices is often driven by curiosity, imitation, boredom, irritation from rhinitis or otalgia, playfulness, and a desire to explore. Clinical presentation depends on the site and nature of the foreign body. In children, a sudden episode of coughing followed by dyspnoea, dysphagia, or excessive salivation should raise suspicion of an airway or oesophageal

foreign body.³ In adults, there is usually a clear history of ingestion or accidental insertion into the ear or nose. Diagnosis may be delayed, particularly in aerodigestive tract foreign bodies, as symptoms are often nonspecific and the inciting event may go unnoticed, leading to misdiagnosis and delayed treatment. Foreign bodies in the oesophagus, especially in adults, are associated with higher complication rates and increased mortality compared to children. Complications range from local infections to severe conditions such as perforation, broncho aspiration, and mediastinitis.^{3,4}

Although considerable attention has been given to complications, hospitalization, and mortality, the impact of the duration between foreign body ingestion and definitive treatment remains inadequately defined. Management strategies depend on the location, size, and type of foreign body, as well as patient age and cooperation. Aural foreign bodies are commonly removed using forceps, suction, or syringing, provided the tympanic membrane is intact. Nasal foreign bodies may be extracted using ring curettes or Eustachian tube catheters. Removal attempts are contraindicated in uncooperative patients, when the foreign body is deeply impacted, when appropriate instruments are unavailable, or when the nature of the object poses a high risk, such as button batteries.⁴ Generally, removal becomes easier with increasing patient age. When difficulty is anticipated, removal under general anaesthesia should be considered to

KEYWORDS: Complicated foreign bodies; Ear; Foreign bodies; Nose; Otorhinolaryngology; Throat.

Cite as: Ali N, Attique M. Foreign bodies in the ear, nose, and throat: clinical challenges and management [Editorial]. *Gomal J Med Sci* 2026 Jan-Mar;24(1):1-2. <https://doi.org/1046903/gjms/24.1.2299>

Corresponding Author:

Dr. Nawazish Ali
H.O, Department of ENT
DHQ Teaching Hospital
Dera Ismail Khan, Pakistan
E-mail: dralinawazish12147@gmail.com

Date Submitted: 06-12-2025
Date Revised: 19-02-2026
Date Accepted: 21-02-2026

prevent complications such as tympanic membrane injury, haemorrhage, aspiration, and psychological trauma in children. Foreign bodies are responsible for approximately 22% of ENT-related complications. While most complications are minor and easily managed, severe outcomes may occur.⁵

Major contributing factors include unskilled removal attempts by laypersons or untrained healthcare providers, lack of medical expertise, inadequate hospital infrastructure, poor public health support,

and prolonged retention of the foreign body. Epidemiological studies demonstrate a high prevalence of ENT foreign bodies in children under ten years of age, with most cases being accidental. The left ear is commonly affected, pain is the most frequent presenting symptom, and the majority of patients recover without complications following timely removal.⁶ In conclusion this highlight the importance of early recognition, prompt referral, and preventive education. Urgent referral to an ENT specialist is mandatory in cases involving airway or oesophageal foreign bodies, button battery ingestion, and occlusive aural foreign bodies, as well as when previous removal attempts have failed, infection is present, or sedation is required. Effective management requires a tailored, interdisciplinary approach, with early ENT specialist involvement to ensure safe, gentle, and non-traumatic removal while minimizing complications.

REFERENCES

1. Srivanitchapoom C, Yata K. Complicated cases in foreign bodies of the ear, nose, and throat: a case series. *Colomb Med.* 2024 Jun 30;55(2):e2045837. <https://doi.org/10.25100/cm.v55i2.5837>
2. A S, D K. Foreign bodies of ear, nose and throat in paediatric age groups: a retrospective study. *J Med Sci Res.* 2025 Apr 2;13(2):150–6. <https://doi.org/10.17727/JMSR.2024/13-26>
3. Udagatti VD, Kumar RD. Foreign bodies in the ear, nose, and throat: our clinical experience and management perspectives. *J Med Sci.* 2025 Aug 1;11(1-4):456–63. <https://doi.org/10.5005/jp-journals-10045-00421>
4. Loperfido A, Mammarella F, Giorgione C, Celebri ni A, Acquaviva G, Bellocchi G. Management of foreign bodies in the ear, nose and throat in pediatric patients: real-life experience in a large tertiary hospital. *Cureus.* 2022 Oct 26;14(10):e30739. <https://doi.org/10.7759/cureus.30739>
5. Paladin I, Mizdrak I, Gabelica M, Golec Parčina N, Mimica I, Batinović F. Foreign bodies in pediatric otorhinolaryngology: a review. *Pediatr Rep.* 2024 Jun 19;16(2):504–18. <https://doi.org/10.3390/pediatric16020042>
6. Lomate S, Ekhar V, Chandankhede V, Shelkar R, Vedi J. A prospective clinical study of foreign bodies in ear, nose and upper aerodigestive tract – our experience. *Indian J Otolaryngol Head Neck Surg.* 2023 Dec 29;75(4):3461–6. <https://doi.org/10.1007/s12070-023-04015-6>

CONFLICT OF INTEREST

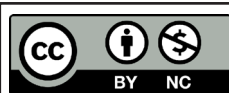
Authors declare no conflict of interest.
GRANT SUPPORT AND FINANCIAL DISCLOSURE
None declared.

AUTHORS' CONTRIBUTION

The following authors have made substantial contributions to the manuscript as under:

| | |
|--|--------|
| Conception or Design: | NA, MA |
| Acquisition, Analysis or Interpretation of Data: | NA, MA |
| Manuscript Writing & Approval: | NA, MA |

All the authors agree to be accountable for all aspects of the work in ensuring that questions related to the accuracy or integrity of any part of the work are appropriately investigated and resolved.



Copyright © 2026. Nawazish Ali, et al. This is an Open Access article distributed under the terms of the Creative Commons Attribution-NonCommercial 4.0 International License, which permits unrestricted use, distribution & reproduction in any medium provided that original work is cited properly.