

REVIEW ARTICLE

QUANTITATIVE LIGHT-INDUCED FLUORESCENCE IN THE DIAGNOSIS OF WHITE SPOT LESIONS: PRINCIPLES, APPLICATIONS, AND CLINICAL RELEVANCE

Namrata Gaur, Raghunath Nagasundara Rao, Jyothikiran Hurkadle, Vidya Gowdappa Doddawad

Departments of Department of Orthodontics and Dentofacial Orthopaedics, JSS Dental College and Hospital, JSS Academy of Higher Education and Research, Mysuru-570015, Karnataka, India

ABSTRACT

White spot lesions (WSLs) are early signs of dental caries and are characterized by demineralization of the enamel surface. Timely detection and monitoring of WSLs are crucial for effective preventive and therapeutic interventions to halt their progression. Quantitative Light-induced Fluorescence (QLF) has emerged as a promising diagnostic tool for the early detection and quantitative assessment of WSLs. This review aims to provide a comprehensive overview of the principles, methodologies, and clinical applications of QLF in diagnosing WSLs. The underlying principles of QLF, including its interaction with dental tissues and the fluorescence properties of demineralized enamel, and methodological aspects, such as image acquisition protocols, software analysis, and interpretation criteria, are critically evaluated. Furthermore, the diagnostic accuracy, reliability, and reproducibility of QLF in detecting WSLs were systematically reviewed based on the available literature. The challenges and limitations associated with QLF, including its reliance on operator proficiency, calibration procedures, and potential confounding factors, have been identified. This review highlights the significance of QLF in enhancing the early detection and management of WSLs, thereby contributing to optimal oral health.

KEYWORDS: Caries; Dental; Fluorescence; Lesions; Light induced; Quantitative; Quantification; White spots.

Cite as: Gaur N, Rao RN, Hurkadle J, Doddawad VG. Quantitative light-induced fluorescence in the diagnosis of white spot lesions: principles, applications, and clinical relevance [review article]. *Gomal J Med Sci* 2026 Jan-Mar;24(1):85-90. <https://doi.org/10.46903/gjms/24.1.2174>

INTRODUCTION

The main objective of orthodontic treatment is to enhance both tooth function and facial aesthetics. To achieve this, orthodontists must provide rigorous preventive care to maintain the tooth structure. Despite taking oral hygiene preventive precautions during fixed orthodontic therapy, some patients present with what is termed as White Spot Lesions (WSL), which can aesthetically compromise the treatment.¹ These lesions present with a demineralized surface of enamel, which is characterized by a white, chalky,

opaque appearance. WSL has the potential to further develop into the most commonly encountered dental problem, dental caries. In fixed orthodontics, WSL appear around the bracket surface.² Poor oral hygiene, along with other factors, including bacterial plaque and inaccessibility while cleaning posterior regions, contribute to the development of white spot lesions. Early intervention is the key to achieving uneventful treatment results. Hence, diagnosis of WSL at an early stage plays a very crucial role in its management.³

A lesion diagnosed by visual inspection can be confirmed using various methods. Often, what we feel is a carious lesion, turns out to be a fluorosis lesion. Thus, there is a need for methods that can quantify clinical judgement. Radiography, fibreoptic transillumination, and dye methods are frequently used to detect carious lesions. However, to quantify a lesion, one needs more in-depth analysis which cannot be detected by the above methods.⁴ For about a decade, some quantitative analysis methods have been developed, namely, the Electronic Caries Monitor, Optical Caries Monitor, Quantitative light-induced

Corresponding Author:

Dr. Vidya Gowdappa Doddawad,
Professor and Head of the Department
Department of oral pathology and microbiology
JSS Dental College and Hospital
JSS Academy of Higher Education and Research
Mysuru-570015, Karnataka, India
E-mail: drvidyagd@gmail.com

Date Submitted: 21-09-2025

Date Revised: 17-01-2026

Date Accepted: 09-02-2026

fluorescence (QLF), and DIAGNOdent. These methods have a promising diagnostic quality and require skills to perform.² Laser light induced fluorescence was established as a diagnostic technique for caries detection in 1980s, in which tooth is illuminated with broad beam blue green laser (488nm).⁵

The QLF method has the potential to quantify a lesion by detecting the amount of mineral loss, the volume of that lesion, and the depth. It displays a fluorescent image of the tooth structure under inspection. This method is suitable for quantifying early lesions on smooth enamel surfaces. This is a relatively technique-sensitive method. The QLF software comes with a special camera feature that emits two different lights: white and blue. A healthy tooth emits relatively uniform fluorescence. However, WSL show relatively lower fluorescence owing to the changed mineral composition of the tooth enamel. This reduced fluorescence is shown by the QLF software by displaying an image as well as the values.⁶ It is a significant non-invasive technique for early caries detection and WSL monitoring.

PATHOGENESIS OF WHITE SPOT LESIONS (WSLS)

WSL is the initial stage of carious lesion development. Their prevalence has been reported to increase, most commonly in orthodontic patients. The development of WSL is attributed to the accumulation of plaque bacteria around the brackets corresponding to poor hygiene practices. The lesions appear clinically whitish, as a result of an optical occurrence, owing to the mineral loss from enamel. As a result of increased enamel porosity, the lesion has minimal translucency. Owing to this surface imperfection, brightness is lost, resulting in diffuse light reflection.⁷ A lesser flow of saliva leads to a lowered buffering action and can in turn worsen the problem, the acid neutralization is restricted, and a natural tendency to remineralize the enamel lowers further. The hydroxyapatite (HAP) from enamel is dissolved and lost in this process due to the acidic surroundings and creation of porosities. With time, the lesions progressed somewhat rapidly. However, they can only be seen when the tooth surface is dry. Therefore, the white spot is associated with the enamel's mineral loss, which is still partially demineralized at the time of diagnosis and is susceptible to remineralization. There is a significant correlation between the lesion intensity and volume. While the intensity provides a clinical picture, the volume of the lesion indicates the depth of involvement. Therefore, early detection of these lesions is key to an effective management strategy.

CONVENTIONAL APPROACHES TO DETECTING WHITE SPOT LESIONS

Various methods have been employed for the detection of early white spot lesions for many years before the advent of advanced technologies. These

methods include:

Visual examination: WSL appear chalky white and opaque, and visual examination is one of the most common methods for detecting a white spot lesion. It is common to miss a lesion during visual inspection. Incorporation of magnifications of resolution up to 0.05mm enhances visual examination and diagnostic quality. A study by Gupta et al noted a significant improvement in WSL detection with magnification loupes compared to that with naked eye detection. However, owing to lesser subjectivity and reproducibility, this method has its own drawbacks.⁸

Tactile Examination: Dental probe or explorer is used to feel the surface for irregularities or soft spots indicating a demineralized surface. It is a subjective and unreliable method, and the diagnosis varies among examiners.⁹

Radiographs (X-rays): Radiographic techniques can reveal the presence of carious lesion but detection of an early white spot lesion is limited with its use.¹⁰

Dyes: Disclosing agents for plaque and WSL are employed by various clinicians to aid in diagnosis. Dyes can be used as an adjunct with light induced fluorescence techniques to enhance diagnostic quality.

Transillumination: This involves a thorough examination of the tooth surface to detect areas of demineralization. This method is clinically significant, but the lack of lesion quantification is a drawback.¹¹

Traditional methods are still valuable in daily practice and are important in a comprehensive dental setup, especially in areas impacted the digital divide. Advancements such as QLF offer a quantitative analysis, enhancing the quality of diagnosis and early prompt management of white spot lesions.

QUANTITATIVE LIGHT-INDUCED FLUORESCENCE:

In recent years, quantitative light-induced fluorescence has been shown to be a promising modality for the early detection of dental caries and white spot lesions. It is based on the principle of fluorescence, where light emitted by an atom or molecule after absorbing electromagnetic radiation is used to detect changes in the tooth structure. Fluorescence is a phenomenon in which light emitted by an atom is absorbed by another atom or molecule. During this absorption, the high-energy state electrons are excited.¹² The electrons rapidly relax to the lowest energy state. After reaching this state, the electrons release energy that is stored in the form of emitted photons. The energy of the absorbed radiation is typically higher than that of the emitted light.

The fluorescent agent absorbs the photons emitted by the fluorescence imaging equipment. Subsequently, the electrons of the agent undergo a Stokes shift, which is a change from the ground state to the excited state and back again. When the electron

energy is released in this final stage, a photon with a wavelength shorter than that of the imaging system is released (Figure 1). The specialised fluorescence camera records this fluorescence signal.¹³

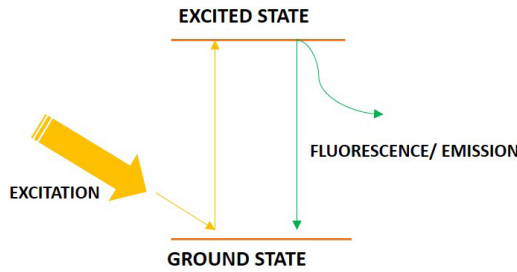


Figure 1- Working Principle of Fluorescence Imaging

During demineralization of enamel, the minerals are replaced by water, which causes lesser resistance to the path of light in the tooth structure.¹⁴ During fluorescence of the enamel post demineralization, the intensity of light absorption decreases in demineralized areas, and thus this portion appears to be darker than the surrounding healthy structure.¹⁵ When tooth enamel is illuminated with blue-green light, it emits fluorescence. Demineralized areas, such as white spot lesions, exhibit reduced fluorescence owing to structural changes in the enamel. QLF systems capture images of the tooth surface under controlled lighting conditions and quantify the fluorescence loss, providing numerical values for lesion severity and remineralization efficacy.¹⁶

Different generations of QLF devices have been developed, from first-generation Inspektor Pro systems to modern devices such as the QLF-D Biluminator™ (Figure 2) and Qraycam. Improvements have led to enhanced imaging quality, faster acquisition times, and better quantification capabilities. QLF systems capture images of the tooth surface under controlled lighting conditions. Image analysis software quan-

tifies fluorescence loss and recovery, generating numerical values for lesion severity and remineralization efficacy.⁵

DIAGNOSTIC EVALUATION OF QLF IN MONITORING WHITE SPOT LESIONS AND MINERAL CHANGES

Quantitative light-induced fluorescence (QLF) has been widely used for the standardized evaluation of enamel demineralization and lesion quantification. Many researchers have employed customized jigs to ensure consistent positioning of samples during image acquisition, typically maintaining a fixed distance—often around 1 cm—between the sample and the QLF camera. Such setups frequently incorporate black acrylic backgrounds to minimize reflective interference and facilitate clear delineation of tooth surfaces for analysis.

QLF imaging systems, such as the customized single-lens reflex (SLR) camera models, are commonly equipped with a 60 mm macro lens, white and blue high-power LEDs, and settings optimized for both white and fluorescent imaging. Typical parameters reported in experimental setups include a shutter speed of approximately 1/30 s, an aperture value near f/20 with an ISO setting of 1600 for white light imaging, and a shutter speed of about 1/10 s with an aperture of f/10 for blue light fluorescence capture. Imaging is generally conducted in dark-room conditions to minimize external light interference.

The captured images are processed using proprietary software, most frequently QA2 (Inspektor Research Systems BV), which enables demarcation of lesion areas, image reconstruction, and quantitative measurement of fluorescence-related parameters. The key metrics assessed include volume ΔQ (volume of the lesion), ΔF (% fluorescence loss, depth of lesion), and ΔF Max (% maximum fluorescence loss).¹⁷ However, it is noted across various reports that QLF analysis cannot reliably differentiate lesions confined to enamel from those extending into dentin.




Figure 2- QLF Biluminator™ with white and blue light imaging

Despite this limitation, several in vitro and in vivo validation studies have confirmed the reproducibility and reliability of QLF measurements using software platforms such as Inspektor™ Pro and QLF-D Biluminator™, which employ similar computational algorithms for fluorescence quantification.¹⁸ Various parameters obtained with QLF software with calibrations are listed in Table 1.¹⁹

Table 1- Various parameters obtained with QLF software with calibrations

Parameters	Symbol	Unit	Description
Delta F	ΔF	%	Fluorescence loss compared with
Delta Q	ΔQ	%·px ²	Fluorescence loss
Lesion Area	A	px ²	Areas
Delta R	ΔR	%	Percentage increase in the ratio of red to green components compared with

The levels measured with the QLF camera are system-specific, and for each camera configuration, the relation between fluorescence and mineral loss, lesion depth, and dentin involvement needs to be calibrated before calculations.²⁰ In a study by van der Veen et al., QLF was used as a diagnostic modality for detecting carious lesions developed post-orthodontic therapy. The parameters used were delta F (%) and area of lesions (mm²) for each lesion. Another in-vitro study by Aljehani et al compared QLF with DIAGNOdent for WSL quantification and concluded QLF to be a better technique for caries detection. Heinrich et al conducted a study for caries detection using QLF and concluded it to be a sensitive method for detection.²¹ Figure 3 displays the images generated with QLF Biluminator™ software and how it is used in for analysis.

APPLICATION AND VALIDATION OF QLF IN CLINICAL DENTISTRY

QLF has been established as a method for diagnosing early white spot lesions. Numerous studies have supported this conclusion. In a study evaluating the assessment of fluorides on WSL, QLF demonstrated to be of great importance in assessing the primary outcome ΔQ and secondary outcome ΔF .²² Another study aimed at assessing the development of WSL using different agents for luting a bonded acrylic splint to achieve rapid maxillary expansion (RME). It used QLF images of before and after RME and concluded it to be a powerful tool for detecting lesions.^{23,24,25} QLF has been validated in numerous other studies to be a reliable method for caries and early WSL detection. It can detect mineral loss, which is usually clinically not visible.²⁶ However, one study concluded that no significant improvement was noted in caries detection using QLF when compared with visual inspection. Amongst the different generations of QLF systems, the second- and third-generation devices were found to have a higher accuracy in mineral loss measurements.²⁷ QLF has also been shown to be more sensitive and specific compared to other methods, such as DIAGNOdent. The QLF software is also well constructed for plaque detection, which is not clinically visible.²⁸ Apart from clinical advantages, it serves as a medium for patient motivation by providing visual feedback on the current status of the lesions.

FUTURE OF QLF IN DIGITAL DENTISTRY AND AI ASSISTED DIAGNOSIS:

With the emergence of artificial intelligence (AI) and image-based diagnosis, the future of QLF is closely related to advances in digital dentistry. By providing a non-invasive, radiation-free, and patient-friendly method for early white spot lesion or caries detection, it becomes an ideal diagnostic setup for AI integration. Analysis of QLF images for the detection of lesions and their progression with AI algorithms can

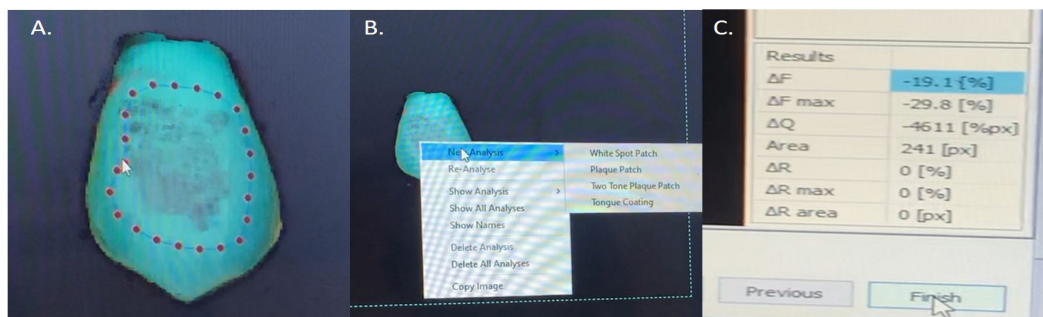


Image showing method of quantitative analysis using QLF software
 A. After selection of the image, mark the area that needs to be analyzed. B. New analysis to be done of the desired parameter, for e.g. White spot patch as shown. C. the software displays the values of various parameters after analysis

Figure 3- QLF Biluminator™ software processing

predict early risk with greater accuracy and precision than manual examination. With the evolution of the digital dentistry platform, QLF has the potential to become a remarkable diagnostic tool. Furthermore, by combining machine learning and QLF, diagnostic reliability can be enhanced and made more accurate, thus reducing human error.²⁸

PATIENT SAFETY CONSIDERATIONS IN QLF TECHNOLOGY

QLF is a significantly reliable method for patient safety. However, it does not include radiation exposure. The apparatus uses light of approximately 406 nm wavelength, which is usually considered within the safety limits. However, strict exposure monitoring is required.^{29,30}

PRACTICAL LIMITATIONS OF QLF IMAGING IN ROUTINE DENTAL DIAGNOSTICS

Despite the several advantages of the QLF system, it has certain limitations in clinical applications. This method is primarily sensitive to smooth surface lesions, and its inclusion of occlusal lesions remains to be investigated. The presence of unwanted plaque, stains, or calculus on the tooth can interfere with the values. Additionally, tooth dehydration can affect image quality. Furthermore, the cost of the equipment and complexity in operating the system poses a great challenge and its use is restricted to trained professionals.³⁰

CONCLUSION

Quantitative Light-Induced Fluorescence (QLF) is a remarkable advancement in the early monitoring of white spot lesions and dental caries. It serves as a valuable tool in decision-making owing to its quantification accuracy of lesion severity. Although it has numerous advantages, future research should focus on overcoming the limitations of the QLF system and expanding its use in dental practice. In addition, the integration of QLF with artificial intelligence can further improve sensitivity and specificity. It also holds growing potential for dental institutions, providing an accurate tool for early caries detection.

REFERENCES:

- Nayak UA, Kailani T, Althagafy R. Microinvasive, esthetic management of white spot lesion following orthodontic treatment using resin infiltration: a case report. *Int J Clin Pediatr Dent.* 2023;16(2):396–9. <https://doi.org/10.5005/jp-journals-10005-2529>
- Oh SH, Lee SR, Choi JY, Choi YS, Kim SH, Yoon HC, et al. Detection of dental caries and cracks with quantitative light-induced fluorescence in comparison to radiographic and visual examination: a retrospective case study. *Sensors (Basel).* 2021;21(5):1741. <https://doi.org/10.3390/s21051741>
- Quinty O, Antonarakis GS, Kiliaridis S, Mavropoulos A. Factors related to bracket bond failure during orthodontic treatment: a single-centre single-operator study. *Dent J (Basel).* 2024;12(10):300. <https://doi.org/10.3390/dj12100300>
- Pretty IA, Ellwood RP. The caries continuum: opportunities to detect, treat and monitor the re-mineralization of early caries lesions. *J Dent.* 2013;41 Suppl 2:S12–21. <https://doi.org/10.1016/j.jdent.2010.04.003>
- Al Saffan AD. Current approaches to diagnosis of early proximal carious lesion: a literature review. *Cureus.* 2023;15(8):e43489. <https://doi.org/10.7759/cureus.43489>
- Güven E, Eden E, Attin R, Firincioğulları EC. Remineralization of post-orthodontic white spot lesions with a fluoride varnish and a self-assembling P11-4 peptides: a prospective in-vivo study. *Clin Oral Investig.* 2024;28(8):464. <https://doi.org/10.1007/s00784-024-05865-2>
- Lopes PC, Carvalho T, Gomes ATPC, Veiga N, Blanco L, Correia MJ, et al. White spot lesions: diagnosis and treatment—a systematic review. *BMC Oral Health.* 2024;24(1):58. <https://doi.org/10.1186/s12903-023-03720-6>
- Amaechi BT, McGarrell B, Luong MN, Okoye LO, Gakunga PT. Prevention of white spot lesions around orthodontic brackets using organoselenium-containing antimicrobial enamel surface sealant. *Heliyon.* 2021;7(3):e06490. <https://doi.org/10.1016/j.heliyon.2021.e06490>
- Macey R, Walsh T, Riley P, Glenny AM, Worthington HV, O'Malley L, et al. Visual or visual-tactile examination to detect and inform the diagnosis of enamel caries. *Cochrane Database Syst Rev.* 2021;6:CD014546. <https://doi.org/10.1002/14651858.CD014546>
- Verma P, Jain RK. Visual assessment of extent of white spot lesions in subjects treated with fixed orthodontic appliances: a retrospective study. *World J Dent.* 2022;13(3):245–9.
- Park SW, Kang SM, Lee HS, Kim SK, Lee ES, Kim BR, et al. Lesion activity assessment of early caries using dye-enhanced quantitative light-induced fluorescence. *Sci Rep.* 2022;12(1):11848. <https://doi.org/10.1038/s41598-022-15862-8>
- Charvat J, Prochazka A, Kucera T, Tichy A, Yurchenko M, Himmlova L. Diffuse reflectance spectroscopy as a novel method of caries detection—an in vitro comparative study in permanent teeth. *Diagnostics (Basel).* 2023;13(11):1878. <https://doi.org/10.3390/diagnostics13111878>
- Galema HA, Meijer RPJ, Lauwerends LJ, Verhoef C, Burggraaf J, Vahrmeijer AL, et al. Fluorescence-guided surgery in colorectal cancer: a review on clinical results and future perspectives. *Eur J Surg Oncol.* 2022;48(4):810–21. <https://doi.org/10.1016/j.ejso.2021.10.005>
- Abdelaziz M. Detection, diagnosis, and monitoring of early caries: the future of individualized dental care. *Diagnostics (Basel).* 2023;13(24):3649. <https://doi.org/10.3390/diagnostics13243649>
- Vinothkumar TS. Application of near-infrared light transillumination in restorative dentistry: a review. *J Contemp Dent Pract.* 2021;22(11):1355–61.
- Nassar HM, Yeslam HE. Current novel caries diagnostic

- technologies: restorative dentists' attitude and use preferences. *Healthcare (Basel)*. 2021;9(10):1387. <https://doi.org/10.3390/healthcare9101387>
17. Kumar H, Sharma K, Kumari A, Singh S, Nandi MK, Banerjee KL. Assessment of white spots with quantitative light-induced fluorescence in patients undergoing fixed orthodontics. *J Pharm Bioallied Sci*. 2021;13(Suppl-1):S312-4. https://doi.org/10.4103/jpbs.JPBS_812_20
 18. Sezici YL, Çınarcık H, Yetkiner E, Attin R. Low-viscosity resin infiltration efficacy on postorthodontic white spot lesions: a quantitative light-induced fluorescence evaluation. *Turk J Orthod*. 2020;33(2):92-7. <https://doi.org/10.5152/TurkJOrthod.2020.19088>
 19. Oh SH, Choi JY, Kim SH. Evaluation of dental caries detection with quantitative light-induced fluorescence in comparison to different field of view devices. *Sci Rep*. 2022;12(1):6139. <https://doi.org/10.1038/s41598-022-10126-x>
 20. Son SA, Jung YH, Kim JH, Park JK. Investigation of validity and inter-examiner agreement of quantitative light-induced fluorescent images in diagnosing cracked teeth. *Sci Rep*. 2024;14(1):32094.
 21. Park KJ, Voigt A, Schneider H, Ziebolz D, Haak R. Light-based diagnostic methods for the in vivo assessment of initial caries lesions: laser fluorescence, QLF and OCT. *Photodiagn Photodyn Ther*. 2021;34:102270. <https://doi.org/10.1016/j.pdpdt.2021.102270>
 22. Lazar L, Vlása A, Beresescu L, Bud A, Lazar AP, Matei L, Bud E. White spot lesions (WSLs)—post-orthodontic occurrence, management and treatment alternatives: a narrative review. *J Clin Med*. 2023;12(5):1908. <https://doi.org/10.3390/jcm12051908>
 23. Cho KH, Kang CM, Jung HI, Lee HS, Lee K, Lee TY, et al. The diagnostic efficacy of quantitative light-induced fluorescence in detection of dental caries of primary teeth. *J Dent*. 2021;115:103845. <https://doi.org/10.1016/j.jdent.2021.103845>
 24. La Rosa GRM, Pedullà E, Chapple I, Pacino SA, Polosa R. The use of quantitative light-induced fluorescence in carious lesion research: a bibliometric review. *J Dent*. 2024;148:105220.
 25. Li J, Zhang R, Wang X. Comparison of three orthodontic bonding systems in white spot lesion development: a randomized clinical trial. *Angle Orthod*. 2023;93(5):5319.
 26. Lee S. Tooth caries classification with QLF images using convolutional neural networks for permanent teeth in vivo. *BMC Oral Health*. 2023;23:3669.
 27. Atilla AO, Ozturk T, Eruz MM, Yagci A. A comparative assessment of orthodontic treatment outcomes using the quantitative light-induced fluorescence (QLF) method between direct bonding and indirect bonding techniques in adolescents: a single-centre, single-blind randomized controlled trial. *Eur J Orthod*. 2020;42(4):441-53. <https://doi.org/10.1093/ejo/cjz058>
 28. Park SW, Kahharova D, Lee JY, Lee ES, de Josselin de Jong E, Khudanov B, et al. Clinical assessment of an automated fluorescent plaque index scoring system with quantitative light-induced fluorescence. *Photodiagn Photodyn Ther*. 2020;32:102011. <https://doi.org/10.1016/j.pdpdt.2020.102011>
 29. Scherl DS, Coffman L, Mansoor A, Rajwa B, Patsekin V, Robinson JP. A semi-automated method for measuring biofilm accumulation on the teeth using quantitative light-induced fluorescence in dogs and cats. *J Vet Dent*. 2022;39(2):122-32. <https://doi.org/10.1177/08987564221081991>
 30. Savas S, Bitisik IN, Izgi M, Kucukyilmaz E. An in vitro comparison of different caries-detection methods in primary molars. *BMC Oral Health*. 2025;25(1):1934. <https://doi.org/10.1186/s12903-025-07359-3>

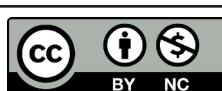
CONFLICT OF INTEREST
 Authors declare no conflict of interest.
GRANT SUPPORT AND FINANCIAL DISCLOSURE
 None declared.

AUTHORS' CONTRIBUTION

The following authors have made substantial contributions to the manuscript as under:

Conception or Design:	NG, RNR
Acquisition, Analysis or Interpretation of Data:	NG, RNR, JH, VGD
Manuscript Writing & Approval:	NG, RNR, JH, VGD

All the authors agree to be accountable for all aspects of the work in ensuring that questions related to the accuracy or integrity of any part of the work are appropriately investigated and resolved.



Copyright © 2026. Namrata Gaur, et al. This is an Open Access article distributed under the terms of the Creative Commons Attribution-NonCommercial 4.0 International License, which permits unrestricted use, distribution & reproduction in any medium provided that original work is cited properly.