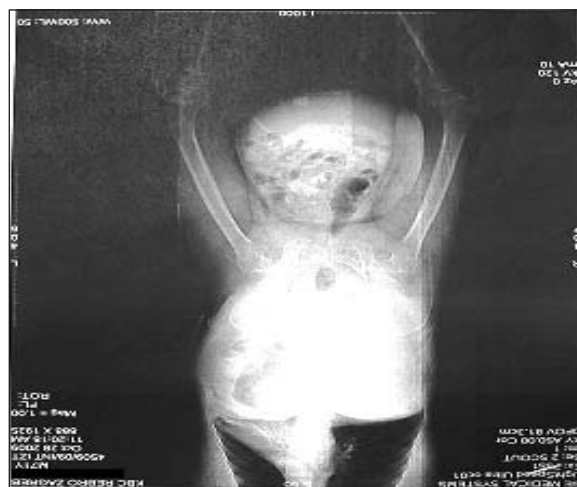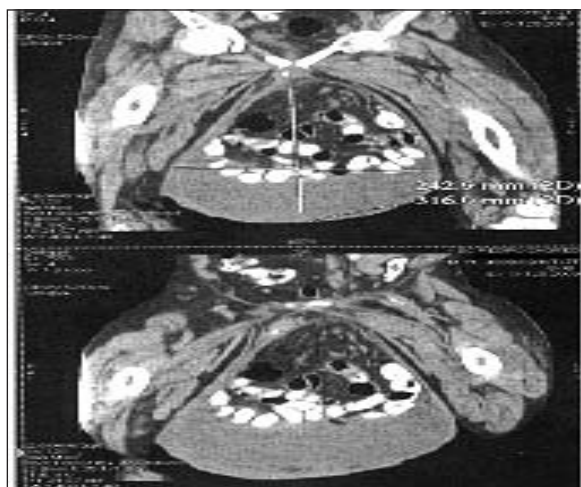

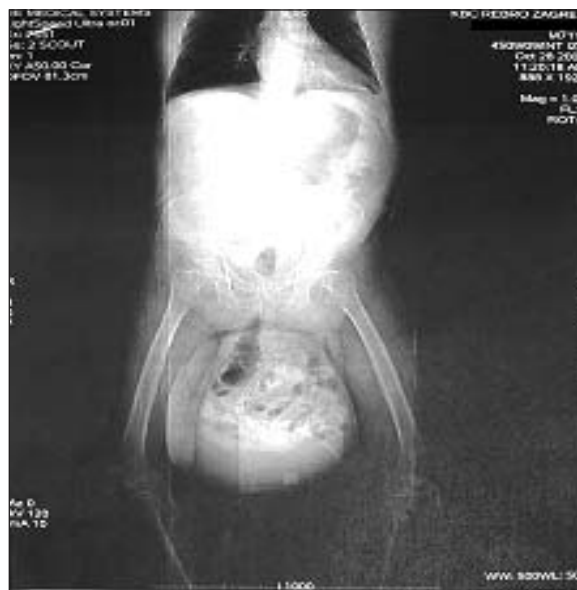
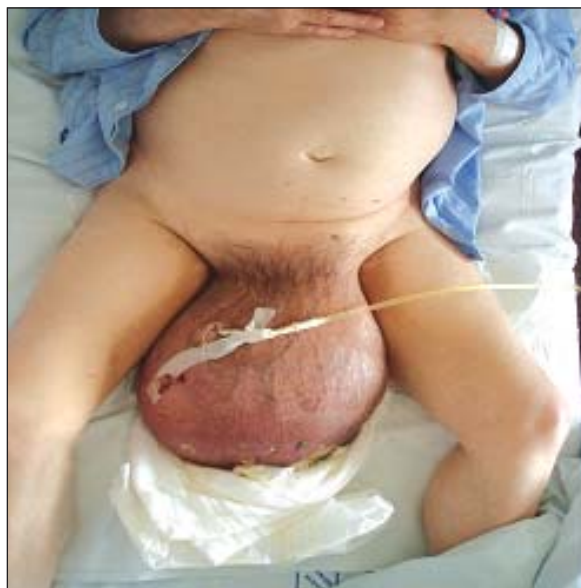## IMAGES IN CLINICAL MEDICINE



### SCROTAL HERNIA MIMICKING A BABYGRAM

A 71 years old male with myelodysplastic syndrome noticed the formation of a scrotal hernia for the last three years. The abdominal surgeon recommended surgery only in vital indication. The hernia kept growing and small skin defects appeared. He had normal bowel movement and urination. During the last hospitalization due to sepsis, CT scan of the lower abdomen was performed which showed a scrotum of 32x24 cm containing small bowel without distension and fluid. Successful treatment with broad spectrum antibiotics was initiated. A surgical operation to reduce the hernia was performed.

We present a CT image turned upside-down which resembles a babygram.

**Marko Baresic, Dubravka Bosnic, Mirna Sentic**

Division of Clinical Immunology & Rheumatology  
Department of Medicine  
University Hospital Center Zagreb  
Kispaticeva 12, 10 000 Zagreb, Croatia  
E-mail: markobaresic@gmail.com