

CASE REPORT

RARE PRESENTATION OF LEGG-CALVÉ-PERTHES DISEASE OF HIP JOINTS

Manickam Vasanthi, Vijayachandra Archana, Ramaswamy Somasekar

Department of Paediatrics, Sree Balaji Medical College and Hospital, Chennai, Tamil Nadu, India

ABSTRACT

Collapse of femoral head due to reduced blood supply and subsequent remodeling of the femoral head is known as Perthes disease. Usual age of presentation is 4 to 10 years. Here we present a child who developed painful limp on the left lower limb on the early days of his third year of life. It was misdiagnosed as synovitis (transient) of the left hip. There was no resolution of the limp, so more investigations were done and he was later found to have Perthes disease.

KEY WORDS: Legg-Calvé-Perthes Disease; Synovitis; Femoral Head; Child; Lower Limb; Hip; Epiphysis.

Cite as: Vasanthi M, Archana V, Somasekar R. Rare presentation of Legg-Calvé-Perthes disease of hip joints [case report]. *Gomal J Med Sci* 2021 Jul-Sep; 19(3):121-2. <https://doi.org/10.46903/gjms/19.03.1037>

INTRODUCTION

Legg-Calvé-Perthes Disease (LCPD) is a hip disorder, probably caused by idiopathic, coagulopathy, thrombophilia, trauma or infections. There is temporary interruption of blood supply to proximal femoral epiphysis. It is a self-limiting disease occurring between 4 to 8 years of age affecting boys more than girls.¹⁻³

CASE REPORT

Six-years-old girl child, first born to non-consanguineous parents presented with complaints of left lower limb pain localized to major joints for eight months, limping for six months and tilting of hip to left side on standing for five months. Child was alert, active with stable vital signs and normal anthropometry for age. Left lower limb was adducted and medially rotated with restricted movements. Trendelenburg gait sign was positive. Limb length discrepancy shows compensation. Bilateral involvement and incidence in female population is a rare presentation of LCPD. Since the child was less than eight years of age with surgical Waldenström stage II (fragmentation phase), she was treated by non-surgical methods and IV Bisphosphonates (Pamidronate).⁴ The recovery of the child was to be followed up by the paediatric orthopaedic

surgeon. However, this child is at risk of recurrence due to bilateral presentation of the disease.⁵

INVESTIGATION

CBC, ESR, ALP, Coagulation profile, Serum calcium, phosphorous were all in normal range. CRP was negative. X-ray and MRI hip joints showed bilateral LCPD, with left Catterall-II stage and Right in Catterall-I stage.

DISCUSSION

There are multiple causes for limping in a child, there are certain conditions in which they require emergency and urgent treatment and these conditions should be given priority during the time of making a diagnosis. Also infectious causes and injury caused due to accident or non-accidental etiology should be considered. If the radiographic imaging and blood investigations are normal; then the cause of limping is not usually an emergency. If there is resolution of the limp within few days of onset; then transient synovitis is a valid diagnosis.

The peak age of incidence of Perthes disease is 5-7 years. Few case reports have showed that Perthes disease has occurred in children even less than three years of age. Avascular necrosis has been reported in young children, following developmental dysplasia of the hip. A close differential diagnosis to this presentation is Meyer's dysplasia. The typical age of presentation of Meyer's disease is two years, more often bilateral and having gender predominance of males over females. X-rays have showed significant retardation in growth of epiphyseal nucleus of femoral bone. The symptoms of Meyer's dysplasia commonly resolve within few weeks and require no treatment and radiological improvement can be noted as early as six years of age.

Corresponding Author:

Dr. Manickam Vasanthi
Resident, Department of Pediatrics
Sree Balaji Medical College and Hospital
Tamil Nadu, India
E-mail: vasanthiimanickam@gmail.com

Date Submitted: 13-04-2021

Date Revised: 02-05-2021

Date Accepted: 12-06-2021

The prognosis of Perthes disease is better when the disease has occurred at a younger age. There is evidence of good outcome on conservative management, without the need for surgical management.

CONCLUSION

Perthes disease is a rare entity. We as treating physicians must keep in mind the different clinical presentations of the disease for early diagnosis and appropriate treatment.

REFERENCE

1. Kliegman RM, St. Geme J. Nelson Textbook of Paediatrics. 21st ed. Elsevier; 2019.
2. Maheshwari J, Mhaskar VA. Textbook of Essential Orthopaedics (including clinical methods). 5th ed. New Delhi: Jaypee Brothers Medical Publishers; 2015.
3. Kim HKW. Legg-Calvé-Perthes Disease. J Am Acad Orthop Surg 2010 Nov;18(11):676-86. <https://doi.org/10.5435/00124635-201011000-00005>
4. Barney J, Piuze NS, Akhondi H. Femoral Head Avascular Necrosis. In: StatPearls [Internet]. Treasure Island (FL): StatPearls Publishing; 2021 Jan [last update 2021 Jul 6, accessed 2021 May 15]. PMID: 31536264NBK546658. Available at: <https://www.ncbi.nlm.nih.gov/books/NBK546658/>
5. Stevens DB, Tao SS, Glueck CJ. Recurrent Legg-Calvé-Perthes Disease: Case report and long-term followup. Clin Orthop Relat Res 2001 Apr;(385):124-9. <https://doi.org/10.1097/00003086-200104000-00020>

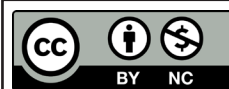
CONFLICT OF INTEREST
Authors declare no conflict of interest.
GRANT SUPPORT AND FINANCIAL DISCLOSURE
None declared.

AUTHORS' CONTRIBUTION

The following authors have made substantial contributions to the manuscript as under:

Conception or Design: MV
Acquisition, Analysis or Interpretation of Data: MV, VA, RS
Manuscript Writing & Approval: MV, VA, RS

All the authors agree to be accountable for all aspects of the work in ensuring that questions related to the accuracy or integrity of any part of the work are appropriately investigated and resolved.



Copyright © 2021. Manickam Vasanthi, et al. This is an Open Access article distributed under the terms of the Creative Commons Attribution-NonCommercial 4.0 International License, which permits unrestricted use, distribution & reproduction in any medium provided that original work is cited properly.